

The “Buckets”: Early Observations on the Use of Red and Infrared Light Helmets in Parkinson’s Disease Patients

Catherine L. Hamilton, MBBS, MPH,¹ Hala El Khoury, BSc,¹ David Hamilton, BSc,¹
Frank Nicklason, MBBS, FRACP,^{1,2} and John Mitrofanis, PhD¹

Abstract

Background: Parkinson’s disease is a well-known neurological disorder with distinct motor signs and non-motor symptoms.

Objective: We report on six patients with Parkinson’s disease that used in-house built photobiomodulation (PBM) helmets.

Methods: We used “buckets” lined with light-emitting diodes (LEDs) of wavelengths across the red to near-infrared range (i.e., 670, 810, and 850 nm; $n=5$) or an homemade intranasal LED device (660 nm; $n=1$). Progress was assessed by the patients themselves, their spouse, or their attending medical practitioners.

Results: We found that 55% of the initial signs and symptoms of the six patients showed overall improvement, whereas 43% stayed the same and only 2% got worse. We also found that PBM did not target a specific sign or symptom, with both motor and nonmotor ones being affected, depending on the patient.

Conclusions: In summary, our early observations are the first to note the impact of PBM on patients’ signs and symptoms over an extended period, up to 24 months, and lays the groundwork for further development to clinical trial.

Keywords: Parkinson’s disease, photobiomodulation, LED helmet, 670 nm, 810 nm

Introduction

THE APPLICATION OF red to near-infrared light ($\lambda=600$ –1070 nm) to body tissues, known also as photobiomodulation (PBM), has been used to treat many neurological conditions in humans, including Parkinson’s disease,^{1–5} Alzheimer’s disease,⁶ depression,^{7,8} traumatic brain injury,^{9,10} age-related macular degeneration,¹¹ stroke,¹² and lower back pain.^{13,14} In each of these explorations, as in all those involving experimental animals,¹⁵ PBM leads to beneficial outcomes, including improved cognition, mood, sight, memory, and movement.

A key feature of PBM, at least from animal models of Parkinson’s and Alzheimer’s disease, is that it can be neuroprotective, being able to slow the degenerative process.^{15–17} This feature makes the treatment most appealing for use in humans, mainly because all of the current treatments for both diseases are symptomatic and not neuroprotective.

In this study, we document six Parkinson’s disease patients who used PBM therapy. Five patients used in-house built helmets, buckets lined with light-emitting diode (LED) devices of wavelengths across the red to near-infrared range (i.e., 670, 810, and 850 nm), whereas one patient used an

homemade intranasal LED device (660 nm). Two of these patients were reported on previously,⁵ but in this study, we provide updates on their progress; the other four were entirely new cases. This report, as with our previous one,⁵ was not part of any systematic research study nor randomized clinical trial with placebo controls, it was simply a series of observations made by the patients, carers and, in particular, their attending medical practitioners. In fact, the first bucket helmets were made by one of medical practitioners (C.H.) to potentially help the patients alleviate their signs and symptoms, many of whom, were referred to by a specialist (F.N.). Even though we had a relatively small number of cases ($n=6$), the early findings were most encouraging. Our report serves to alert others with similar conditions of the potential benefits of PBM therapy and forms a template for future clinical trials.^{18,19}

Case Descriptions

In the section below, the impact of PBM will be described separately for each patient. The use of PBM was voluntary and progress was assessed by the patients themselves, their carer, and in particular their attending medical practitioners

¹Department of Anatomy F13, University of Sydney, 2006, Sydney, Australia.

²Geriatric Medicine, Royal Hobart Hospital, Hobart, Australia.

(general practitioner and geriatrician). In fact, the medical practitioners (C.H. and F.N.) were in a position to monitor all six patients, hence providing some consistency in the overall assessment. All patients consented for their case to be included in this report.

Tables 1 and 2 show various features of the bucket helmets constructed for each patient, their main signs and symptoms, together with the impact of PBM. As is evident from Table 1, the different patients had a range of different signs and symptoms, reflective of the heterogeneous nature of the disease.^{20,21} Further, there were some variations in the construct of the bucket helmets in the different cases, because each was built as each new patient came on board to try them out. Some of the details of power and energy for the bucket helmets were not known, but what we did know is noted in Tables 1 and 2. The one, major factor that the different bucket helmets did have in common, and in fact made them unique, was that they all incorporated two wavelengths, in the red (e.g., 670 nm) and near-infrared (e.g., 810 and 850 nm) ranges. The use of the two wavelengths was because animal experiments have shown that using two wavelengths, sequentially, offers more beneficial outcomes than just the one wavelength alone.²²

Patient PN

PN, a 63-year-old male, was diagnosed two and a half years previously. His major signs and symptoms included: resting tremor, akinesia, gait change, impaired fine motor skills and facial movement, trouble sleeping and swallowing, persistent cough, fatigue, low self-esteem, and depression (Table 1). His daily medications included levodopa/carbidopa and benzotropine.

Nine months after diagnosis, PN started using a PBM helmet, a modified bucket lined internally with strips of 670 and 810 nm LEDs (e.g., Fig. 1A, B; redlightsonthebrain.blog; Table 1). His exposure was 10 min for each wavelength twice daily. Four weeks after first use, there was a noticeable reduction in his tremor. After 8 weeks, he was walking faster, sleeping better, had more facial animation, more energy, coughed less, swallowed more easily, and felt more confident and less depressed. Over the next few months, all of these improvements stabilized, and PN and his family felt that PBM had restored many features of his previous day-to-day activities and self-confidence. His overall fine motor function had improved also and he resumed home renovations.

For a more objective analysis, we measured PN's writing by using ImageJ software. Figure 2A shows a sample of a seven-word sentence that he wrote before PBM therapy began (time point 1) and after 24 months (time point 5). This last time point was a new addition to our analysis; our previous analysis of PN's writing spanned only 10 months.⁵ The words were outlined (red lines, Fig. 2A) and the program calculated the area (Fig. 3A) and the perimeter of distance (Fig. 3B) of each word. Our analysis indicated that, although there was a reduction at time point 5, this change did not reach significance for either area (Fig. 3A; ANOVA one-way: $F=0.7$, $p=0.61$) or perimeter of distance (Fig. 3B; ANOVA one-way: $F=0.6$, $p=0.68$) of each word ($n=7$). Hence, over this extensive 2-year period, there was no clear deterioration in his writing, it still being very legible.

In summary, of PN's 12 initial signs and symptoms, including writing, eleven improved (90%) after PBM, while one stayed the same (10%) and none deteriorated (Fig. 4; Table 1). His medication during this period did not change. In recent times, PN has started using a "Well Red Coronet" (e.g., Fig. 1C, D), made from thin aluminium sheets lined with red (670 nm) and near-infrared (810 nm) LEDs (www.wellred.com.au).

Patient MH

MH, a 61-year-old male, was diagnosed 6 years previously. His major signs and symptoms included: resting tremor, impaired fine motor skills and facial movement, gait change (reduced stride), fatigue, apathy, difficulty maintaining thoughts, low self-esteem, hesitant speech, and trouble sleeping. His daily medications included levodopa/carbidopa.

Three and half years after diagnosis, MH started using a 670 and 810 nm LED bucket (redlightsonthebrain.blog). His exposure time was 10 min for each wavelength twice daily (Table 1). After a month, MH reported that he had resumed his usual activities, was more confident, socially interactive, and could think more clearly. Over the next few months, improvements in his sleep, speech, and gait became evident, together with his face being more animated. Further, MH reported that he had much more energy and reduced tremor. Over the next 2 years, these improvements have been maintained and he enjoys an active lifestyle. About 12 months previously, he developed dystonia in this right foot, together with a sleep disturbance (dream enactment). These have not however, deteriorated any further over the last 12 months. His fine motor skills have improved also; he recently resumed being able to tie a fly onto a fishing line and he now requires little help doing up his shirt buttons.

Figure 2B shows a sample of a 13-word sentence that MH wrote before PBM therapy began (time point 1) and after 24 months (time point 5). The graphs in Fig. 3 indicate no differences in either area (Fig. 3A; ANOVA one-way: $F=0.4$, $p=0.71$) or perimeter of distance (Fig. 3B; ANOVA one-way: $F=0.3$, $p=0.77$) of each word analyzed ($n=13$). Hence, although no improvements were evident, there was no deterioration over this extensive period. It should be noted that our original analysis of MH's writing—that spanned only 3 months—indicated an improvement in area and perimeter of words.⁵ Our current, more extensive analysis of his writing spanning 24 months, showed that his writing stabilized and, most importantly, did not get worse.

In summary, of MH's eleven initial signs and symptoms, including his writing, seven improved (~90%) after PBM, while one stayed the same (~10%) and none deteriorated (Fig. 4; Table 1). His medication during this period did not change. MH developed dystonia and dream enactment 12 months ago and they have not deteriorated any further since then. Recently, MH has started using a coronet also (e.g., Fig. 1C and D).

Patient CB

CB, a 64-year-old male, was diagnosed 12 years previously. His daily medications were an apomorphine pump, apomorphine hydrochloride, levodopa, and benserazide. His major signs and symptoms were: slow gait, muscle spasms

TABLE 1. TABLE SUMMARIZING THE DIFFERENT PROTOCOLS, BUCKET DEVICES, FEATURES OF DISEASE, AND EFFECTS OF PHOTBIOMODULATION ON THE SIX PATIENTS IN THIS REPORT

<i>Patient</i>	<i>Disease duration</i>	<i>Wavelengths and dose protocol</i>	<i>Start of PBM after diagnosis</i>	<i>PBM duration</i>	<i>Start of beneficial PBM effects</i>	<i>PBM impact on motor signs</i>	<i>PBM impact on nonmotor symptoms</i>
PN (63 years old)	2.5 Years	670+810 nm 10 min/twice daily	9 Months	24 Months	1 Month	Tremor (✓), akinesia (✓), gait (✓), fine motor skills (✓), facial movement (✓), writing (-)	Sleeping (✓), swallowing (✓), cough (✓), fatigue (✓), self-esteem (✓), depression (✓)
MH (61 years old)	6 Years	670+810 nm 10 min/twice daily	3.5 Years	24 Months	1 Month	Tremor (✓), fine motor skills (✓), facial movement (✓), gait (✓), writing (-)	Fatigue (✓), apathy (✓), thinking (✓), self-esteem (✓), speech (✓), sleeping (✓)
CB (64 years old)	12 Years	670+850 nm 20 min/daily	11 Years	12 Months	8 Months	Gait (✓), muscle spasms (-), stiffness (-), lockouts (✓), writing (-)	Swallowing (-), speech (✓), bladder urgency (-), itchiness (-), sleeping (-), stress (✓), low self-esteem (✓), social interaction (✓), depression (✓)
SS (64 years old)	4 Years	670+810 nm 30 min/daily	2 Years	12 Months	3 Months	Tremor (x), gait (✓), muscle cramps (✓), stiffness (✓), writing (-)	Constipation (-), sweating (✓), swallowing (-)
TU (73 years old)	14 Months	670+810 nm 30 min/daily	14 Months	14 Months	14 Months	Tremor (-), writing (-)	Dream enactment (-)
ML (75 years old)	14 Years	660 nm (nasal) 20 min/day	~13 Years	8 Months	8 Months	Tremor (-), cogwheel rigidity (-), facial movements (✓), gait (-), writing (-)	Smell (-), fatigue (✓), anxiety (-), thinking (-), urinary frequency (✓), constipation (✓), memory (-), depression (✓), sleep (✓), restless leg (-), dream enactment (✓)

The symbol (✓) next to a sign or symptom represents an improvement after PBM, while the symbol (-) represents no change and the symbol (x) represents a worsening of PBM, photobiomodulation.

TABLE 2. TABLE TO REPORT BUCKET PARAMETERS IN PATIENTS

Manufacturer	C & D Hamilton
Model identifier	Eliza
Year produced	2016
No. and type of emitters (laser or LED)	670 nm and 810 ($n=150$); 850 nm ($n=120$) All as LED strips
Wavelength and bandwidth (nm)	670 nm, 810 nm, 850 nm; bandwidth unknown
Pulse mode (CW or Hz, duty cycle)	Continuous wave
Beam spot size at target (cm^2)	N/a
Irradiance at target (mW/cm^2)	N/a
If pulsed peak irradiance (mW/cm^2)	N/a
Exposure duration (sec)	670 nm, 810 nm, 850 nm; 600–900 sec
Radiant exposure (J/cm^2)	670 nm = 6.96 W used, efficiency unknown 810 nm = 26.4 W used, efficiency unknown 850 nm = 6 W used, efficiency unknown
Radiant energy (J)	Variable, range unknown
No. of points irradiated	N/a
Area irradiated (cm^2)	Head
Application technique	Transcranial
No. and frequency of treatment sessions	1–2 Daily
Total radiant energy over entire treatment course (J)	Ongoing

LED, light-emitting diode.

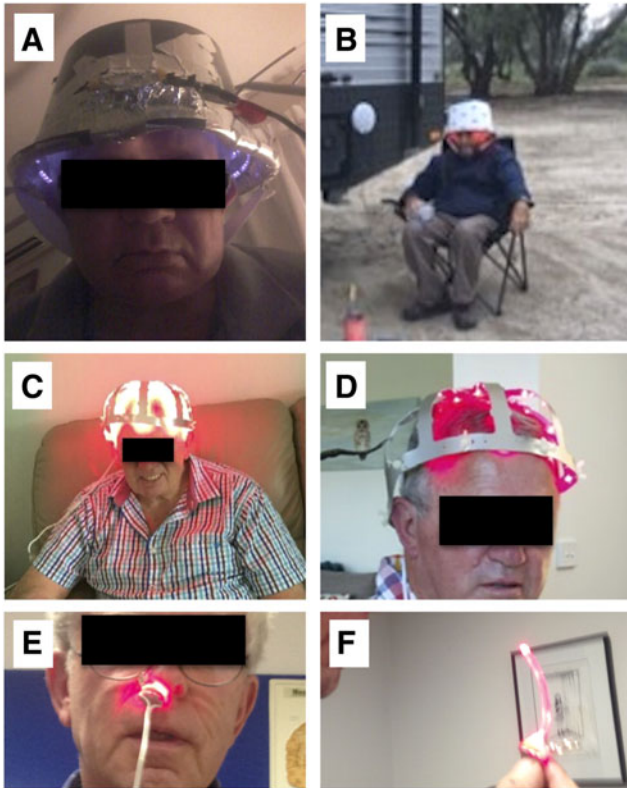

FIG. 1. The light “bucket” helmets, lined with red (670 nm) and near-infrared (810 and 850 nm) LED lights. The original helmets were constructed from either buckets (A); patient CB or lampshades (B); patient MH. Some patients—CB (C), PN (D), MH, SS—have recently started using the “coronets,” made from thin aluminium sheets lined with red (670 nm) and near-infrared (810 nm) LEDs (www.wellred.com.au). (E, F) A homemade intranasal device of 660 nm LED used by one of the patients (ML). LED, light-emitting diode.

and stiffness, trouble swallowing, soft voice, bladder urgency, itchy feet, difficulty sleeping, and stress. He suffered from “lockouts,” during which he would feel “frozen with stiffness.” These occurred in the periods when the apomorphine pump was switched off, every 2 h. During these lockouts, CB used a rescue dose of apomorphine. His condition had made social interaction very difficult, he had poor tolerance to change in daily routine, his enjoyment of life was limited, and his confidence was low.

Some 11 years after diagnosis, CB started using a 670 nm LED bucket; 4 months later, 850 nm LEDs were added and he used the two wavelengths forthwith (redlightsonthebrain .blog). His exposure time was 20 min/day (Table 1). After 8 months, CB and his wife noted some subtle but distinct changes. They found that his daily number of lockouts had reduced; on most days, where he would suffer three a day, he now suffered none. He still had the occasional lockout however, and on these “bad” days, they tended to be more intense than before. Nevertheless, their frequency was lower. CB also measured the amount of time between his levodopa medication. Before PBM therapy, he would medicate every 75 min, while with PBM, this had increased to 90 min. A small, yet consistent difference. His speech had more volume and was a little quicker than before. His gait improved also, being quicker and with more arm movement. CB’s anxiety improved and with it, his ability to tolerate routine changes and social interactions. His wife commented that he was now able to do more and they “have more of a life now.”

Figure 3 shows an analysis of CB’s writing over a period of 12 months. There was little change in either area (Fig. 3A; ANOVA one-way: $F=0.3$, $p=0.89$) or perimeter of distance (Fig. 3B; ANOVA one-way: $F=1.2$, $p=0.32$) of each word analyzed ($n=11$). Hence, although no improvements were evident, there was no deterioration over this 12-month period.

In summary, of CB’s 14 initial signs and symptoms, including his writing, 7 improved ($\sim 50\%$) after PBM, while 7 stayed the same ($\sim 50\%$) and none deteriorated (Fig. 4;

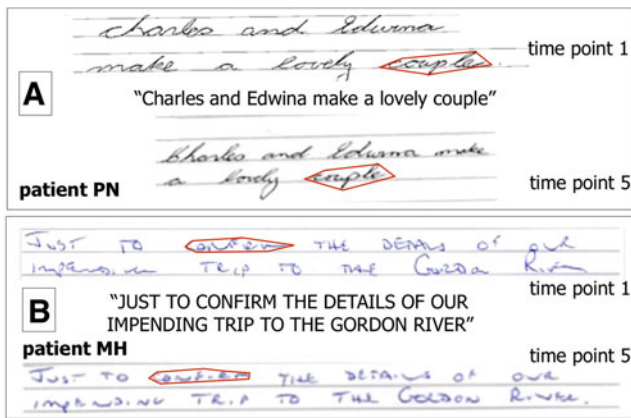


FIG. 2. Analysis of writing from patient PN (A) and MH (B): analysis from before light (time point 1) and during its course (time point 5), 24 months after commencement of therapy. Each word of their sample was outlined (red lines) and the program calculated the area and perimeter of distance of the words.

Table 1). His medication during this period did, in fact, reduced slightly. Recently, CB has started using a coronet (e.g., Fig. 1C and D).

Patient SS

SS, a 64-year-old male, was diagnosed 4 years previously. His medications were levodopa and carbidopa twice daily. His major signs and symptoms were: resting tremor, gait change, muscle cramps and stiffness, constipation, profuse sweating on exertion, and difficulty swallowing.

Two years after diagnosis, SS started using a 670 nm LED bucket (redlightsonthebrain.blog) for 30 min daily (Table 1). After 3 months, SS and his wife reported faster times for his daily run. This was followed at 8 months by improvements in his walking, being much quicker and with more arm movement. At about this time, SS added 810 nm LEDs to his bucket, and used the two wavelengths sequentially for 15 min daily. He also noted improvements in sweating, muscle cramps, and stiffness. His tremor however, fluctuated on a day-to-day basis. At 5 months after first use of PBM therapy, his medication was increased from two to three times per day, in response to his tremor fluctuations. The improvements in SS's running, sweating, muscle cramps, and stiffness were evident before this increase occurred.

Figure 3 shows an analysis of SS's writing over a period of 12 months. There was little change in either area (Fig. 3A; ANOVA one-way: $F=0.4$, $p=0.8$) or perimeter of distance (Fig. 3B; ANOVA one-way: $F=0.2$, $p=0.91$) of each word analyzed ($n=12$). Hence, although no improvements were evident, there was no deterioration over this period.

In summary, of SS's eight initial major signs and symptoms, including his writing, four improved (~55%) after PBM, while three stayed the same (~35%) and one deteriorated (10%; Fig. 4; Table 1). Although his medication did increase during this period, many of SS's improvements were evident before this increase occurred. Recently, SS has started using a coronet (e.g., Fig. 1C and D).

Patient TU

TU, a 73-year-old male, was diagnosed over 14 months previously, having developed a resting tremor in his right hand. He also, on occasion, suffered from dream enactment. Otherwise, he was free of the usual Parkinsonian signs and symptoms, for example, akinesia and postural instability. Levodopa was tolerated poorly and discontinued quickly.

Soon after diagnosis, TU started using a 670 and 810 nm LED bucket (redlightsonthebrain.blog), 15 min each wavelength daily (Table 1). After 14 months, TU's tremor was observed by his attending medical practitioners to be no worse than at diagnosis and, on some occasions, not evident at all. The frequency of his dream enactments had not changed also, still being "occasional." Further, even after this extended time period, he had not developed any other Parkinsonian sign or symptom.

Figure 3 shows an analysis of TU's writing over a period of 14 months. There was little change in either area (Fig. 3A; ANOVA one-way: $F=0.3$, $p=0.88$) or perimeter of distance (Fig. 3B; ANOVA one-way: $F=0.2$, $p=0.91$) of each word analyzed ($n=9$). Hence, although no improvements were evident, there was no deterioration over this period.

In summary, although there was no clear improvement in TU's two initial signs and symptoms after PBM, they, including his writing, all stabilized and did not get any worse (Fig. 4; Table 1). He is still not on any medication. Recently, TU has started using a coronet (e.g., Fig. 1C and D).

Patient ML

ML, a 75-year-old male, was diagnosed 14 years previously. His major signs and symptoms were: tremor, cogwheel rigidity, impaired facial movements and gait, diminished sense of smell, fatigue, anxiety, slowed thinking, mild urinary frequency and constipation, memory impairment, depression, troubled sleep, restless leg, and dream enactment. His daily medications included levodopa/carbidopa, rasagiline and pramipexole. He was also using an antidepressant (venlafaxine) at the time and had trialed isradipine (a calcium channel blocker).

ML is a retired general surgeon and an amateur electronics buff. Rather than make a bucket, he developed an intranasal red light (660 nm) device that he could insert a fair distance through the nasal cavity (~7 cm; Fig. 1E, F), placing the PBM source tip close to the bone that covers the brainstem (i.e., sphenoid). His thinking was to get the PBM source as close to the diseased brainstem dopaminergic neurons as possible. With some skepticism, ML commenced treatment with his intranasal device, for 20 min/day, about 8 months ago (Table 1).

Soon thereafter the first use of his device, ML started feeling much better. His wife (who also has a medical degree), and attending medical practitioner, concurred with his much improved status, noting his better mood, improved facial movements, and energy. ML's urinary frequency and constipation resolved, his sleep was much improved, and there was less dream enactment. Over the next few months these improvements continued, so much so that ML felt "on top of the world."

Figure 3 shows an analysis of ML's writing from two sentence samples; one spans a period of about 2 years (ML1), while the other spans a period of 11 years (ML2). The two samples were different sentences, each from time points well before and during PBM therapy. There was little

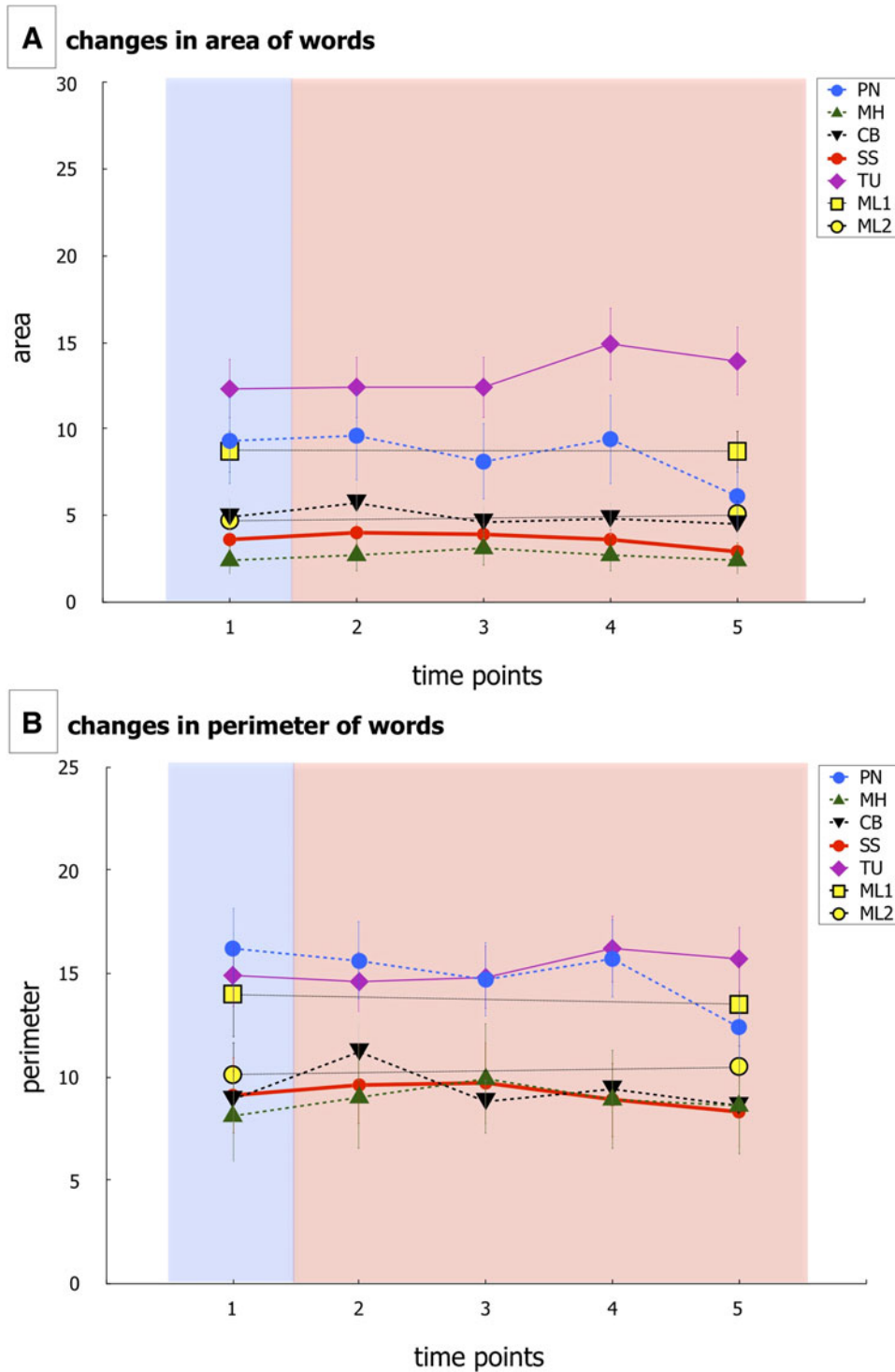


FIG. 3. Graphs show means and SEMs: (A) shows changes in area if words while (B) shows changes in perimeter of words for each patient. The data for each patient are represented with a different color and/or symbol (see key). The blue shading represents the analysis before onset of light (time point 1), whereas the red shading represents the period during light therapy (time points 2–5). In most cases, the period of light therapy was rather extensive up to 14 months. Note for the patients that we have provided updates for (RP and MH), their data were either reanalyzed (e.g., new words) or data from new samples were added. SEM, standard error of the mean.

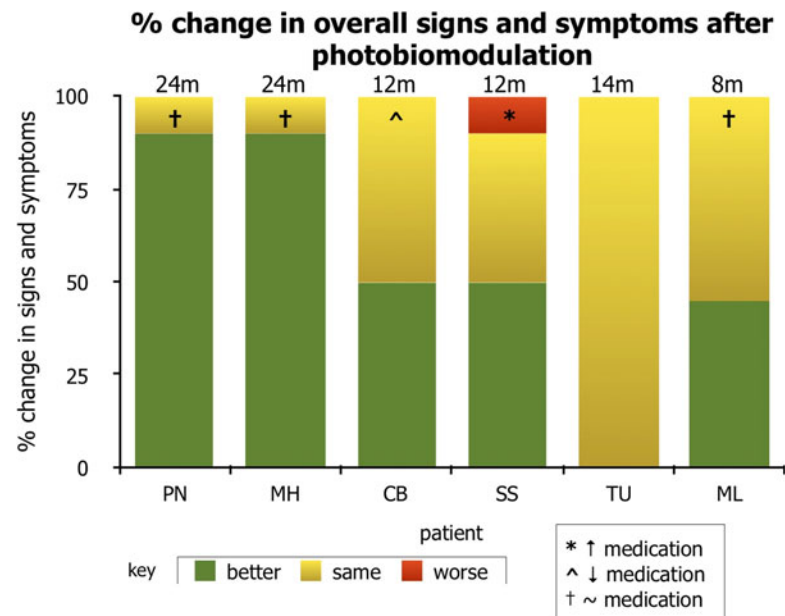
change in either area (Fig. 3A; *t*-test, two-tailed, unpaired: ML1 $p=0.98$, ML2 $p=0.65$) or perimeter of distance (Fig. 3B; *t*-test, two-tailed, unpaired: ML1 $p=0.70$, ML2 $p=0.77$) of each word analyzed (ML1 $n=28$; ML2 $n=25$). Hence, although no improvements were evident, there was no deterioration over these extended periods.

In summary, of ML's 16 major signs and symptoms, including his writing, 7 improved ($\sim 45\%$) after PBM, while 9 stayed the same ($\sim 55\%$) and none deteriorated (Fig. 4; Table 1). His medication did not increase during this period.

Discussion

This study follows on from our previous exploration into the impact of PBM on four movement disorder patients using PBM buckets.⁵ In this study, we describe six cases of Parkinson's disease patients, five using buckets and one, an intranasal device. Two of these patients were cases that we have reported on previously,⁵ but we provide further updates on their progress, while the other four were entirely new case reports. Our report is the first to document the impact of

FIG. 4. Graphs showing the % change in overall signs and symptoms of each patient after light therapy. Of the initial signs and symptoms in each patient, the majority showed overall improvement (green regions), a minority stayed the same (yellow), and none got worse (red). Any changes in medication during this time period for each patient is indicated also (see legend). The numbers on top of each column represent the time period (in months) each patient was using during light therapy.



PBM on patients over an extended period, at 8 ($n=1$), 12 ($n=2$), 14 ($n=1$), and 24 ($n=2$) months.

When taken all together, we found that 55% of the initial signs and symptoms of the six patients showed overall improvement, whereas 43% stayed the same and only 2% worsened (Fig. 4). These values assume considerable significance in view of the long-term nature of our analysis and observations, from 8 to 24 months. These findings indicated a stabilization of signs and symptoms that only one sign from all of the six patients (2% of total) worsened during PBM therapy. This feature is highlighted by our objective analysis of their writing, where no patient suffered a major decline in the area and perimeter of words, together with overall writing legibility. Given the progressive nature of the disease,^{21,22} this stabilization of writing (and other signs and symptoms) over such a considerable period, was striking. Although one cannot predict the precise time course of the different signs and symptoms of the disease in different individuals, with the disease often not progressing in a straight line,^{21,22} the fact that the majority of the signs and symptoms across our six patients did not worsen during PBM was very encouraging. We should note also that many of these PBM-induced changes were not typical of the placebo phenomenon, in that they were slow in onset and sustained. Further, they were often observed by the carer or, in particular, the medical practitioners (general practitioner and geriatrician) rather than the patient themselves.⁴

As with our previous study,⁵ we found that PBM did not target a specific sign or symptom, but rather it impacted on both motor signs and nonmotor symptoms, depending on the patient. Indeed, from our experience, Parkinson's disease patients consistently report that among their signs or symptoms, the ones that they most want to improve are the nonmotor symptoms and that these are the ones that very much reduce their quality of life.^{21,23} Most patients using PBM experience improvement in nonmotor symptoms, especially mood, anxiety, sleep, confidence, apathy, and fatigue.

We were confident that our findings in the six patients were due to their use of PBM and not to anything else, such as changes in medication. Indeed, during their period of PBM

therapy, two patients had no changes in medication (PN, ML), while two had reductions (MH, CB). Patient SS had an increase in medication, but many of his improvements (see Results section), were evident before this increase, suggestive that the improvements were PBM- rather than drug induced.

The factors that generated these stabilizations and improvements are not known, but we suggest the following. For the buckets, the PBM can penetrate to the cerebral cortex and could have influenced the functional activity of its resident neurons directly,⁴ by stimulating mitochondrial activity and the expression of various stimulatory genes.¹⁵ Indeed, PBM has been shown to change the activity of seemingly "normal" neurons.^{24,25} This mechanism may have underpinned some of the improvements, for example in movement, mood, and confidence, seen in our patients. The buckets covered most of the cranium and hence PBM was in a position to influence a range of functionally distinct cortical areas, from prefrontal to motor.⁴ Such a mechanism would however, be more symptomatic, than neuroprotective. The transcranial PBM therapy from the buckets cannot reach the diseased dopaminergic neurons in the brainstem and hence not in a position to influence their survival by direct stimulation.¹⁵⁻¹⁷ PBM from the buckets could, however, have a neuroprotective effect by an indirect stimulation, through the circulation. PBM has been shown to stimulate circulatory cells, for example those of the immune system²⁶ that may then swarm to the distressed brainstem neurons and helps them survive. We know that in animal models, such a mechanism—the abscopal effect—can be neuroprotective.^{15-17,27} It should be noted that for patient ML, who used an intranasal device, PBM would have been much closer to the brainstem than when delivered from the buckets. In his case, PBM may well have penetrated to the brainstem and influenced the diseased neurons directly, stimulating their mitochondria and expression of genes associated with survival,¹⁵ thence being neuroprotective by a direct stimulation.

In conclusion, it is clear that considerably more research, at both basic science and clinical levels, is required to understand better the impact of PBM in Parkinson's disease. For now, our explorations into the PBM-induced effects on

patients were most encouraging (this study⁵) and lay the template for the further development to clinical trial and as a viable therapeutic option.^{19,20}

Acknowledgments

The authors thank Light Ahead, Inc. for provision of the PBM devices and Ron Brown for assistance in the development of the PBM devices.

Author Disclosure Statement

C.H. is a cofounder of Well Red Coronet helmets and is the author of redlightsonthebrain.blog. The authors declare no other conflict of interest.

References

- Zhao G, Guo K, Dan J. 36 case analysis of Parkinson's disease treated by endonasal low energy He-Ne laser. *Acta Acad Med Qingdao Univ [Chinese]* 2003;39:398.
- Maloney R, Shanks S, Maloney J. The application of low-level laser therapy for the symptomatic care of late stage Parkinson's disease: a non-controlled, non-randomized study. *Am Soc Laser Med Surg Abs 30th ASLMS Conference, Phoenix* 2010;185.
- Burchman M. Using Photobiomodulation on a severe Parkinson's patient to enable extractions, root canal treatment, and partial denture fabrication. *J Laser Dent* 2011;19:297–300.
- Hamilton C, Hamilton D, Nicklason F, et al. Exploring the use of transcranial photobiomodulation in Parkinson's disease patients. *Neural Regen Res* 2018a;13:1738–1740.
- Hamilton C, Hamilton D, Nicklason F, et al. Transcranial photobiomodulation therapy: observations from four movement disorder patients. In: *Photobiomodulation in the Brain*. Vol. in press. MR Hamblin and Y Huang Eds. San Diego, CA: Elsevier Academic Press. 2018; Chapter 37: pp.463–472. <https://doi.org/10.1016/B978-0-12-815305-5.00033-6>.
- Saltmarche AE, Naeser MA, Ho KF, et al. Significant improvement in cognition in mild to moderately severe dementia cases treated with transcranial plus intranasal photobiomodulation: case series report. *Photomed Laser Surg* 2017;35:432–441.
- Schiffer F, Johnston AL, Ravichandran C, et al. Psychological benefits 2 and 4 weeks after a single treatment with near infrared light to the forehead: a pilot study of 10 patients with major depression and anxiety. *Behav Brain Funct* 2009;5:46.
- Cassano P, Cusin C, Mischoulon D, et al. Near-infrared transcranial radiation for major depressive disorder: proof of concept study. *Psychiatry J* 2015;2015:352979.
- Naeser MA, Saltmarche A, Krengel MH, et al. Improved cognitive function after transcranial, light-emitting diode treatments in chronic, traumatic brain injury: two case reports. *Photomed Laser Surg* 2011;29:351–358.
- Naeser MA, Zafonte R, Krengel MH, et al. Significant improvements in cognitive performance post-transcranial, red/near-infrared light-emitting diode treatments in chronic, mild traumatic brain injury: open-protocol study. *J Neurotrauma* 2014;31:1008–1017.
- Merry G, Dotson R, Devenyi R, et al. Photobiomodulation as a new treatment for dry age related macular degeneration. Results from the Toronto and Oak Ridge Photobiomodulation Study in AMD (TORPA). *Invest Ophthalmol Vis Sci* 2012;53:2049.
- Lapchak PA, Salgado KF, Chao CH, et al. Transcranial near-infrared light therapy improves motor function following embolic strokes in rabbits: an extended therapeutic window study using continuous and pulse frequency delivery modes. *Neuroscience* 2007;148:907–914.
- Chow RT, Armati PJ. Photobiomodulation: implications for anesthesia and pain relief. *Photomed Laser Surg* 2016;34:599–609.
- Holanda VM, Chavantes MC, Silva DFT, et al. Photobiomodulation of the dorsal root ganglion for the treatment of low back pain: a pilot study. *Lasers Surg Med* 2016;48:653–659.
- Hamblin MR. Shining light on the head: photobiomodulation for brain disorders. *BBA Clin* 2016;6:113–124.
- Johnstone DM, Moro C, Stone J, et al. Turning on lights to stop neurodegeneration: the potential of near infrared light therapy in Alzheimer's and Parkinson's disease. *Front Neurosci* 2016;9:500.
- Mitrofanis J. Why and how does light therapy offer neuroprotection in Parkinson's disease? *Neural Regen Res* 2017;12:574–575.
- Handley MA, Lyles CR, McCulloch C, Cattamanchi A. Selecting and improving quasi-experimental designs in effectiveness and implementation research. *Annu Rev Public Health* 2018;39:5–25.
- Graham JE, Karmarkar AM, Ottenbacher KJ. Small sample research designs for evidence-based rehabilitation: issues and methods. *Arch Phys Med Rehabil* 2012;93(8 Suppl):S111–S116.
- Kalia LV, Kalia SK, Lang AE. Disease-modifying strategies for Parkinson's disease. *Mov Disord* 2015;30:1442–1450.
- Poewe W, Seppi K, Tanner CM, et al. Parkinson disease. *Nat Rev Dis Prim* 2017;3:17013.
- Reinhart F, Massri NE, Torres N, et al. The behavioural and neuroprotective outcomes when 670 nm and 810 nm near infrared light are applied together in MPTP-treated mice. *Neurosci Res* 2017;117:42–47.
- Poewe W. Non-motor symptoms in Parkinson's disease. *Eur J Neurol* 2008;15 Suppl 1:14–20.
- Konstantinović LM, Jelić MB, Jeremić A, et al. Transcranial application of near-infrared low-level laser can modulate cortical excitability. *Lasers Surg Med* 2013;45:648–653.
- Romeo S, Vitale F, Viaggi C, et al. Fluorescent light induces neurodegeneration in the rodent nigrostriatal system but near infrared LED light does not. *Brain Res* 2017;1662:87–101.
- Muili KA, Gopalakrishnan S, Meyer SL, et al. Amelioration of experimental autoimmune encephalomyelitis in C57BL/6 mice by photobiomodulation induced by 670 nm light. *PLoS ONE* 2012;7:e30655.
- Liebert A, Bicknell B, Adams R. Protein conformational modulation by photons: a mechanism for laser treatment effects. *Med Hypothesis* 2014;82:275–281.

Address correspondence to:
John Mitrofanis, PhD
Department of Anatomy F13
University of Sydney
Sydney 2006
Australia

E-mail: john.mitrofanis@sydney.edu.au

Received: April 15, 2019
Accepted after revision: June 18, 2019
Published online: September 18, 2019.